

# Tumor Above the Spinal Accessory Nerve in Papillary Thyroid Cancer That Involves Lateral Neck Nodes

## A Common Occurrence

James F. Pingpank, Jr, MD; Aaron R. Sasson, MD; Alexandra L. Hanlon, PhD; Craig D. Friedman, MD; John A. Ridge, MD, PhD

**Objective:** To describe the nature and extent of lateral neck node metastases from papillary thyroid cancer in relation to presenting physical examination and staging radiologic studies.

**Design:** Retrospective study.

**Setting:** Tertiary referral cancer center.

**Patients:** Consecutive patients who underwent comprehensive neck dissection with or without concurrent thyroidectomy for well-differentiated thyroid cancer between 1991 and 2001. Excluded were patients with well-differentiated thyroid cancer diagnosed incidentally at the time of treatment of other primary head and neck cancer, those with previous neck dissection for nonthyroid malignancies, and those undergoing surgery for medullary thyroid cancer.

**Interventions:** All pathology and operative and preoperative radiology reports for patients undergoing comprehensive neck dissection for well-differentiated thyroid malignancy were reviewed. Data were collected on previous procedures, preoperative evaluation, operative details, and pathologic findings.

**Main Outcome Measure:** Identification of metastatic thyroid cancer in one or more nodes in anatomi-

cally defined drainage basins of the central and lateral neck.

**Results:** A total of 51 neck dissections were performed. All patients had preoperative evidence of metastatic disease. In addition to the usual comprehensive node dissection encompassing all lymphatic tissue in levels II through V, level I nodes and level II nodes above the spinal accessory nerve were labeled as distinct regions in 16 (31%) and 34 (67%) specimens, respectively. Disease was confined to a single nodal level in 20 (39%) of 51 specimens and was present in 4 or more levels in 7 (14%) of 50 neck dissections. There was cancer at 2 or 3 levels in 16 (31%) and 15 (29%) cases, respectively. Seven (21%) of the 34 patients undergoing separate analysis of nodes from above the spinal accessory nerve had cancer there. In 3 of the 34 it was the sole disease in level II.

**Conclusions:** Tumor involvement at multiple nodal levels occurs in most cases when patients have lateral cervical node metastases. "Skip" metastases and cancer above the spinal accessory nerve are common. Neck dissections should include all node stations likely to be involved because selective node excision is likely to leave metastatic disease in situ.

*Arch Otolaryngol Head Neck Surg.* 2002;128:1275-1278

From the Head and Neck Surgery Section, Department of Surgical Oncology (Drs Pingpank, Sasson, Friedman, and Ridge), and the Departments of Radiation Oncology and Biostatistics (Dr Hanlon), Fox Chase Cancer Center, Philadelphia, Pa.

**T**HE EXTENT of surgery required for adequate removal of well-differentiated thyroid cancer has been debated. In the absence of evidence of metastatic disease, disagreement over the need for partial (lobe and isthmus) vs complete (total or near total) thyroidectomy has yet to be settled.<sup>1-5</sup> Indeed, some researchers have even advocated prophylactic cervical lymphadenectomy for high-risk lesions.<sup>6-8</sup> In a disease with an expected overall survival of greater than 90%, only large, impractical trials could answer such questions. Thus, retrospective reviews assume heightened importance.

The effect of small remaining tumor burden after thyroidectomy is not clear.

Several studies have pointed to the frequency of subclinical nodal metastases in high-risk patients.<sup>9-11</sup> Postoperative thyroid suppression with thyroid hormone replacement and the treatment of metastatic and residual disease with radioactive iodine have allowed successful nonoperative management of low-volume cervical disease.<sup>10,12</sup> Several studies have pointed to the presence of lateral cervical nodal disease as an increased risk for local recurrence and/or decreased survival.<sup>1,13-15</sup> To not expend radioactive iodine in the treatment of resectable palpable disease, we pursue an aggressive surgical approach to the management of clinically evident cervical metastasis from well-differentiated thyroid cancer.

**Table 1. Previous Surgical Procedures\***

| Previous Procedures                     | No. (%) of Patients |
|---|---------------------|
| Diagnostic only                         |                     |
| FNA only                                | 6 (14)              |
| Previous surgery and FNA                | 4 (9)               |
| Remote resection                        |                     |
| Total or near-total thyroidectomy       | 6 (14)              |
| Inadequate cancer surgery               |                     |
| Excisional biopsy of neck mass          | 16 (36)             |
| Thyroidectomy and node picking          | 7 (16)              |
| Previous neck dissection                | 1 (2)               |
| Other                                   |                     |
| Incidental finding at unrelated surgery | 1 (2)               |
| None (FNA at FCCC)                      | 3 (7)               |

\*FNA indicates fine-needle aspiration; FCCC, Fox Chase Cancer Center, Philadelphia, Pa.

An accurate appraisal of residual disease is an important component of treatment planning. This report describes the extent of disease present in the lateral cervical nodes of patients presenting with clinically apparent nodal metastasis.

## METHODS

We undertook a retrospective review of all neck dissections performed for well-differentiated thyroid cancer (with or without concurrent thyroidectomy) by 2 attending surgeons (J.A.R. and C.D.F.) at the Fox Chase Cancer Center, Philadelphia, Pa, between 1991 and 2001. Operations included unilateral and bilateral neck dissections (synchronous or staged) performed with or without total or completion thyroidectomies. Procedures for medullary and anaplastic thyroid were excluded from this analysis, as were procedures performed on patients with previous neck dissections for squamous cell cancers of the head and neck. An additional patient with an incidentally discovered papillary thyroid cancer in a single node of neck dissection for squamous cell cancer was excluded from this analysis.

Pathology reports from all procedures related to the diagnosis of thyroid cancer were reviewed for information related to primary tumor stage as well as the number and location of involved nodes. A node was considered positive if there was gross or microscopic evidence of thyroid cancer. Node location was classified by either the operating surgeon or the attending pathologist based on operative labeling. Patients undergoing operative procedures and biopsies of primary tumors and nodes at outside institutions had specimens reviewed at the Fox Chase Cancer Center.

Records were reviewed and data collected regarding patient age, sex, tissue diagnosis, date of initial diagnosis, previous operative procedures, and preoperative examination. Operative reports were reviewed and data collected regarding intraoperative labeling of nodal basins and the presence of additional extranodal disease, including residual or recurrent disease in the thyroid bed. Pathology reports were examined for tumor size, capsular invasion, presence of nonnodal metastases, number and location of all lymph nodes, and the number and location of tumor-bearing nodes.

The number of nodes containing metastatic disease was tabulated. The nodal level(s) were identified, and the number of nodes in a given level was noted for each patient. The overall number of nodes resected, the number of those containing metastatic disease, the number of nodal levels with disease, and the number of patients with disease at a specific level were recorded. Patients were assessed for the presence of uninvolved

node levels between those with metastatic disease ("skip metastasis"). The number of patients was noted with metastases to level II above the spinal accessory nerve and in level I.

Patients presenting with evidence of metastatic thyroid cancer underwent fine-needle aspiration of the suggestive mass if no previous tissue diagnosis had been obtained. In the presence of a concurrent thyroid cancer where malignancy was strongly suspected in palpable nodes, neck dissection was undertaken without proof of neck metastases. All patients underwent excision through an extended collar incision, with modifications made to encompass any previous thyroid or neck incisions. Incisions were carried laterally to the posterior border of the sternocleidomastoid and superiorly to the mastoid process. Scars from previous incisions were excised in their entirety. The thyroid bed was examined, and any residual thyroid tissue or recurrent tumor was removed. A comprehensive neck dissection was undertaken, including levels II through V in all cases. Level I was dissected as a separate specimen when clinically indicated. Level II nodal tissue above the spinal accessory nerve was regularly removed. Sometimes it was taken as a separate specimen. A central node dissection was undertaken in all patients without such a previous lymphadenectomy. Whenever possible, the internal jugular vein, sternocleidomastoid muscle, and the spinal accessory nerve were preserved.

## RESULTS

A total of 51 neck dissections were performed for well-differentiated thyroid cancer in 44 patients between 1991 and 2001. Unilateral neck dissection was performed in 37 patients (84%) and bilateral procedures in 7 (16%). Of those undergoing bilateral procedures, 3 patients had both sides operated on during a single procedure while the remaining 4 had staged procedures. For those undergoing staged procedures, the time between operations ranged from 7 to 55 days. A pathologic diagnosis of papillary cancer or one of its variants was present in all 44 patients. Patient age ranged from 16 to 83 years (median age, 41 years). Women accounted for 23 (52%) of the 44 patients. Three patients were excluded from this analysis: 1 with a previous neck dissection for laryngeal cancer, 1 with an incidentally discovered thyroid nodal metastasis at neck dissection for an oral cavity squamous cell cancer, and a third patient whose papillary cancer was found during prophylactic dissection for medullary carcinoma.

Assessment of primary tumor stage revealed T1 lesions in 11 patients (25%), T2 lesions in 9 (21%), and T4 tumors in 23 (52%). There was a single patient (2%) with a T3 lesion. The number of resected lymph nodes per specimen ranged from 15 to 79 (median, 40). All patients underwent comprehensive neck dissection, with 45 (88%) of 51 being type 3 dissections, preserving the spinal accessory nerve, internal jugular vein, and the sternocleidomastoid muscle. Types 1 and 2 neck dissections were performed in 4 and 2 patients, respectively.

Demographic information was gathered on all patients (n=44). Previous thyroid or lateral cervical surgery had been performed in 41 (93%) of 44 patients (**Table 1**). All 3 patients without previous procedures underwent fine-needle aspiration at our institution. Previous fine-needle aspiration was the sole procedure performed in 10 patients (23%), including 6 patients without previous thyroid cancer and 4 with a remote history of malignancy. Six patients (14%) had a history of thyroid cancer and had no

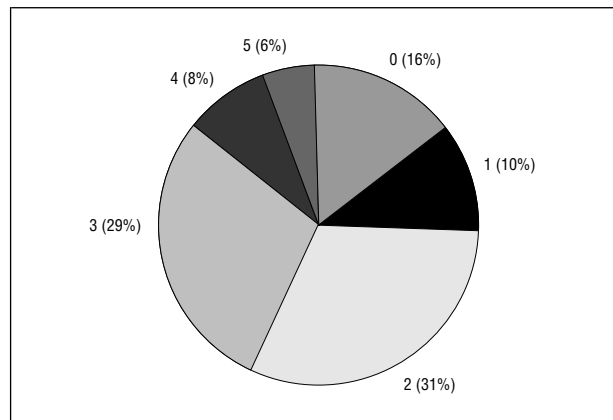
additional procedures performed in the face of clinical recurrence. Inadequate surgical therapy for clinically apparent metastatic disease had been attempted immediately prior to referral to our institution in 24 patients (55%), including excisional biopsy of a lateral neck mass (16 patients), "node picking" at the time of thyroidectomy (7 patients), and limited neck dissection (1 patient). A single additional patient was diagnosed when a node containing thyroid cancer was noted in a pathology specimen obtained during a procedure for thoracic outlet syndrome.

All lateral neck dissection specimens were analyzed separately (N=51) (**Figure 1**). At neck dissection, disease was confined to a single nodal level in 10 lateral node basins (20%) and was present in 4 or more levels in 7 (14%) of 51 specimens. Metastases were present at 2 levels in 16 (31%) and 3 levels in 15 (29%) specimens. Discontinuous nodal involvement (defined by the presence of a disease-free level between 2 tumor-bearing node regions) was observed in 7 (18%) of the 38 neck dissections containing metastatic disease at multiple levels (**Figure 2**). In addition to standard node dissection, level I nodes and level II nodes above the spinal accessory nerve were labeled as distinct regions in 16 (31%) and 34 (67%) specimens, respectively. In 6 (12%) of 51 node dissections, metastases were present in level I. In all instances, nodal disease was present in other areas of the neck. Seven (21%) of the 34 specimens obtained from above the spinal accessory nerve had cancer. In 3 of the 34 it was the sole disease in level II.

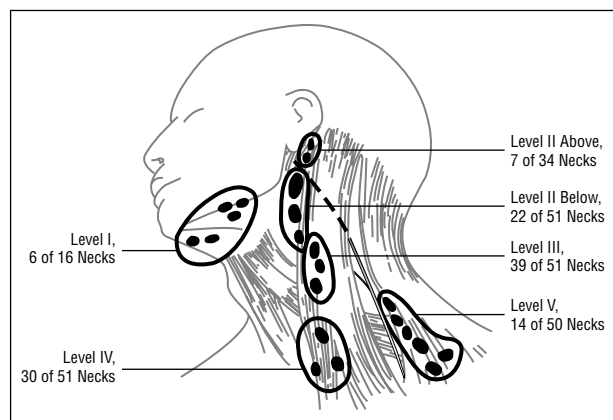
For patients presenting after an excisional biopsy as their only surgical intervention in the neck (n=16), additional nodal disease was found in 13 patients (81%). The number of additional positive nodes ranged from 3 to 24 (mean, 9 nodes) in these 13 patients. Two of the 3 patients without lateral node metastases had paratracheal nodal metastases at surgery. In this group of 16 patients, 7 (44%) had no evidence of additional disease by preoperative physical or radiologic examination, and 1 patient (6%) had disease detected by magnetic resonance imaging only. Eight patients (50%) had additional disease evident on physical examination. A primary thyroid lesion was evident in 9 (56%) of the 16 patients preoperatively, and cancer was found in all 16 pathologic specimens. Six of the primary tumors were 5 mm or less in diameter.

After complete pathologic examination, 8 node specimens (16% of neck dissections) had no evidence of nodal metastases in the lateral neck dissection specimen (**Table 2**). Three of these patients had undergone a previous excisional biopsy as their only surgical intervention and thus had neck dissections performed with a thyroidectomy. In 2 of the 3 patients, extrathyroid disease was found in central or paratracheal nodes. A fourth patient who had undergone previous node picking at the time of thyroidectomy was found to have disease only in the central compartment on reexploration. The remaining 4 patients had extrathyroid disease but none in lateral cervical nodes (including 2 patients undergoing bilateral neck dissections, with nodal disease on one side and an isolated paratracheal node on the other).

Intermediate-term follow-up was available on a sizeable portion of this patient population.<sup>16</sup> Among 38 patients, there was a disease-related mortality of 11%, uni-



**Figure 1.** Number of node basins involved with tumor. Any node in level I through level V that contained gross or microscopic evidence of malignancy was considered involved with tumor. Of the 51 neck dissections performed, multiple levels were involved in 36 specimens (75%).



**Figure 2.** Nodes removed at neck dissection for metastatic, well-differentiated thyroid cancer. Comprehensive neck dissection for clinical lateral cervical metastases includes levels II, III, IV, and V. In addition, level II above the spinal accessory nerve and level I were submitted separately in 34 and 16 cases, respectively. Each level had cancer present in the number of specimens indicated.

versally associated with the presence of systemic disease. Lateral neck control was achieved in 35 (80%) of 44 necks dissected.

#### COMMENT

Cervical metastases of papillary thyroid cancer are common. Factors having an effect on survival include age, sex, stage, tumor size and grade, and the extent of disease (including the presence of cervical metastases).<sup>1,3,12,17,18</sup> Rates of cervical metastases ranging from 11% to 80% (influenced by the nature and timing of neck dissection) have been reported. The prevalence of cervical metastases is highest when prophylactic neck dissections are performed and lower when selective dissections are performed. In the latter situation, the presence of cervical metastases clearly correlates with decreased local control and survival.<sup>1</sup> This has not proven true for microscopic disease found at prophylactic dissection. Although several studies have suggested increased disease-free and overall survival in patients with more extensive thyroid surgery, no series has examined the

**Table 2. Previous Procedures and Findings in Patients With Node-Negative Pathology Specimens**

| Previous Procedure        | No. of Nodes Retrieved at Operation | Additional Findings   |
|---------------------------|-------------------------------------|---|
| Excisional biopsy         | 40                                  | 3-mm occult primary tumor   |
| Excisional biopsy         | 40                                  | 3-mm occult primary tumor, positive central nodes   |
| Excisional biopsy         | 73                                  | 5-mm occult primary tumor, positive paratracheal nodes  |
| Node picking              | 47                                  | Positive central compartment nodes  |
| Thoracic outlet procedure | 33                                  | 1.5-cm primary tumor, positive central and supraclavicular nodes                              |
| Subtotal thyroidectomy    | 19                                  | Massive recurrence, node vs residual thyroid  |
| Thyroidectomy             | 28                                  | T4 primary tumor, positive paratracheal nodes, positive contralateral cervical nodes          |
| Thyroidectomy             | 28                                  | 5-mm occult primary tumor, positive paratracheal nodes, positive contralateral cervical nodes |

effect of the completeness of neck dissection on regional control and survival with cervical metastases.

The present series illustrates the limitations of physical examination in evaluation of the degree of cervical node involvement with papillary thyroid cancer. Disease was limited to a single node basin in only 20% of patients (n=9), while it was present in 4 or more levels in 14% of patients (n=7). The number of positive nodes ranged from 1 to 49 (mean, 7.2 nodes; median, 5 nodes). Additionally, while 75% of patients in this study had nodal disease at multiple levels (n=33), an intervening node level without disease was present in 7 of 38 patients. We have termed these *skip metastases*, and their biologic significance is unknown. As suggested by sentinel node distribution in thyroid and other diseases, the belief in orderly progression of lateral nodal metastases from one nodal basin to another may be invalid. The presence of any clinically apparent disease within one lateral neck nodal basin indicates substantial risk for disease at additional levels. In patients presenting after local excision of presumed isolated metastatic disease, 13 (81%) of 16 had additional nodal metastases on complete node excision. Two of the remaining 3 patients had extrathyroid metastatic disease in the ipsilateral neck. These data indicate that simple excision of the only clinically apparent tumor will seldom eradicate all neck disease.

An additional area of our investigation centered around nodes sometimes omitted from neck dissections for thyroid cancer. Nodes in level I were resected as a separate specimen primarily in patients with clinical lymphadenopathy and were found to contain metastases in 6 (38%) of 16 patients. All patients had disease elsewhere in the neck at full dissection. Some surgeons end dissection of the level II node at the spinal accessory nerve. We regularly carried the dissection above cranial nerve XI and usually examined the tissue in level II above the spinal accessory nerve as a separate specimen. Metastatic disease was present in 7 (21%) of the 34 procedures in which a separate specimen above the spinal accessory nerve was submitted. It was the sole source of disease in level II in 3 of 7 patients with cancer there. These nodes could not have been removed in a limited procedure based on preoperative examination.

In summary, the presence of a single lateral cervical nodal metastasis in patients with or without a previous diagnosis of thyroid cancer signified the presence of additional extrathyroidal disease in 43 (98%) of 44 patients in this series. Additionally, metastases were pres-

ent at multiple nodal levels in the overwhelming majority of patients with lateral cervical metastases. Cancer in nodes above the spinal accessory nerve is common, as are skip metastases. We recommend comprehensive neck dissection for patients with lateral cervical metastases to address all stations likely to be involved. Selective node excision is not likely to extirpate all disease.

Accepted for publication April 1, 2002.

Corresponding author and reprints: John A. Ridge, MD, PhD, Department of Surgical Oncology, Head and Neck Surgery Section, Fox Chase Cancer Center, 7701 Burholme Ave, Philadelphia, PA 19111 (e-mail: JA\_Ridge@fccc.edu).

## REFERENCES

- McConahey WM, Hay ID, Woolner LB, van Heerden JA, Taylor WF. Papillary thyroid cancer treated at the Mayo Clinic, 1946 through 1970: initial manifestations, pathologic findings, therapy, and outcome. *Mayo Clin Proc.* 1986;61:978-996.
- Cunningham MP, Duda RB, Recant W, Chmiel JS, Sylvester JA, Fremgen A. Survival discriminants for differentiated thyroid cancer. *Am J Surg.* 1990;160:344-347.
- DeGroot LJ, Kaplan EL, McCormick M, Straus FH. Natural history, treatment, and course of papillary thyroid carcinoma. *J Clin Endocrinol Metab.* 1990;71:414-424.
- Mazzaferri EL, Jhiang SM. Long-term impact of initial surgical and medical therapy on papillary and follicular thyroid cancer. *Am J Med.* 1994;97:418-428.
- Noguchi M, Katev N, Miyazaki I. Controversies in the surgical management of differentiated thyroid carcinoma. *Int Surg.* 1996;81:163-167.
- Orsenigo E, Beretta E, Mari G, et al. Modified neck dissection in the treatment of differentiated thyroid carcinoma. *Eur J Surg Oncol.* 1997;23:286-288.
- Noguchi S, Murakami N, Yamashita H, Toda M, Kawamoto H. Papillary thyroid carcinoma. *Arch Surg.* 1998;133:276-280.
- Ohshima A, Yamashita H, Noguchi S, et al. Indications for bilateral modified radical neck dissection in patients with papillary carcinoma of the thyroid. *Arch Surg.* 2000;135:1194-1198.
- Noguchi S, Noguchi A, Murakami N. Papillary carcinoma of the thyroid, I: developing pattern of metastasis. *Cancer.* 1970;26:1053-1060.
- Carcangiu ML, Zampi G, Rosai J. Papillary thyroid carcinoma: a study of its many morphologic expressions and clinical correlates. *Pathol Annu.* 1985;20(pt 1):1-44.
- McGregor GI, Luoma A, Jackson SM. Lymph node metastases from well-differentiated thyroid cancer: a clinical review. *Am J Surg.* 1985;149:610-612.
- Simpson WJ, Panzarella T, Carruthers JS, Gospodarowicz MK, Sutcliffe SB. Papillary and follicular thyroid cancer: impact of treatment in 1578 patients. *Int J Radiat Oncol Biol Phys.* 1988;14:1063-1075.
- Mazzaferri EL. Papillary thyroid carcinoma. *Semin Oncol.* 1987;14:315-332.
- Akslen LA. Prognostic importance of histologic grading in papillary thyroid carcinoma. *Cancer.* 1993;72:2680-2685.
- Scheumann GF, Gimm O, Wegener G, Hundeshagen H, Dralle H. Prognostic significance and surgical management of locoregional lymph node metastases in papillary thyroid cancer. *World J Surg.* 1994;18:559-567.
- Pingpank JF, Sasson AR, Hanlon AP, LeVoyer T, Friedman C, Ridge JA. Regional neck failure after comprehensive neck dissection for papillary thyroid cancer is uniformly fatal [abstract]. In: *Proceedings of the American Thyroid Association*. Falls Church, Va: American Thyroid Association; 2001.
- Byar DP, Green SB, Dor P, et al. A prognostic index for thyroid carcinoma. *Eur J Cancer.* 1979;15:1033-1041.
- Hay ID, Bergstralh EJ, Goellner JR, Ebersold JR, Grant CS. Predicting outcome in papillary thyroid carcinoma. *Surgery.* 1993;114:1050-1057.